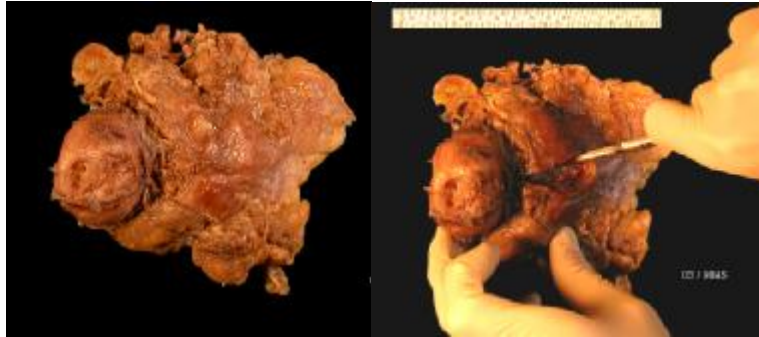
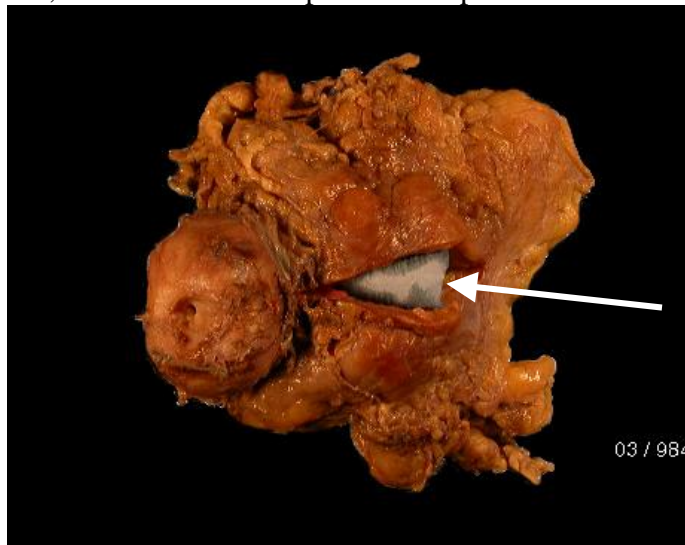


Cystoprostatectomy cut up

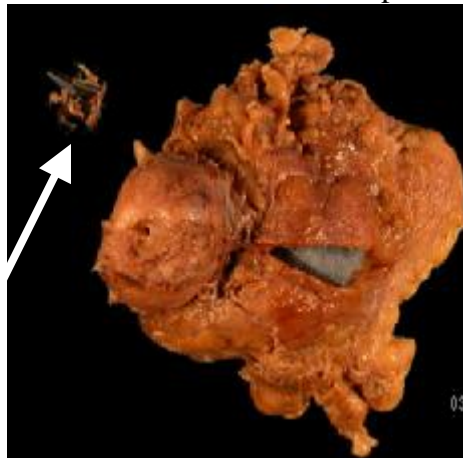
1. Orientate specimen and open the anterior wall of the bladder but not the prostate.



2. Wash out blood, remove catheter if present and pack the lumen with tissue.

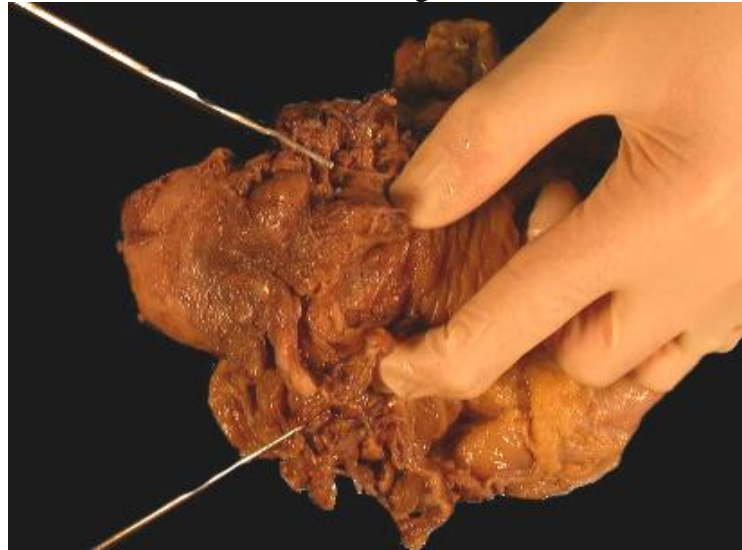


3. Fix for 24hrs (minimum).
4. Describe the bladder, prostate, ureter & vas lengths and any tumour/ulcer.
5. If tumour is present describe the level of invasion (eg inner muscle, through muscle).
6. Remove **ALL STAPLES & SUTURES** from the prostate.




Author: Jon Oxley
Authorised by:
Date: 23/08/2004

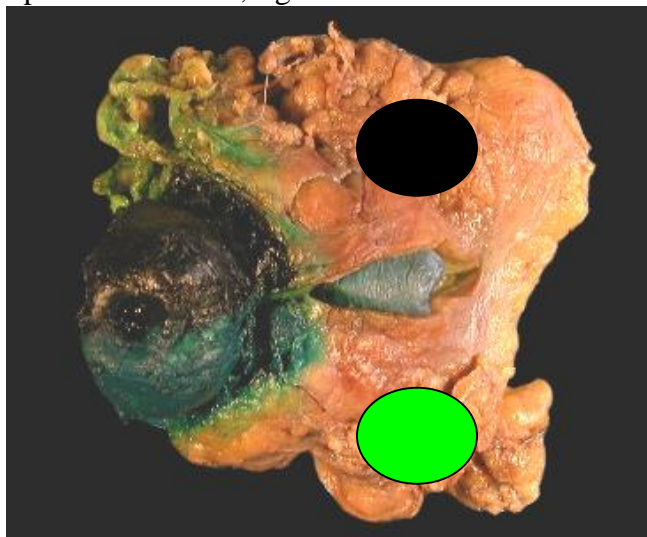
7. Photograph any relevant macro. [dictate macro photos taken]
8. Identify the ureteric and vas resection margins.



9. Sample the ureteric and vas margins.

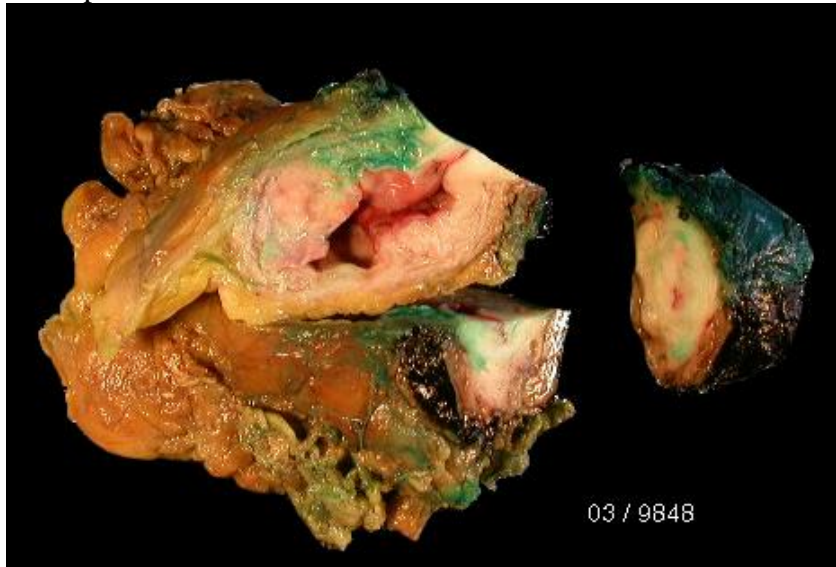


10. Ink left side of prostate GREEN, right side BLACK.



Author: Jon Oxley
Authorised by:
Date: 23/08/2004

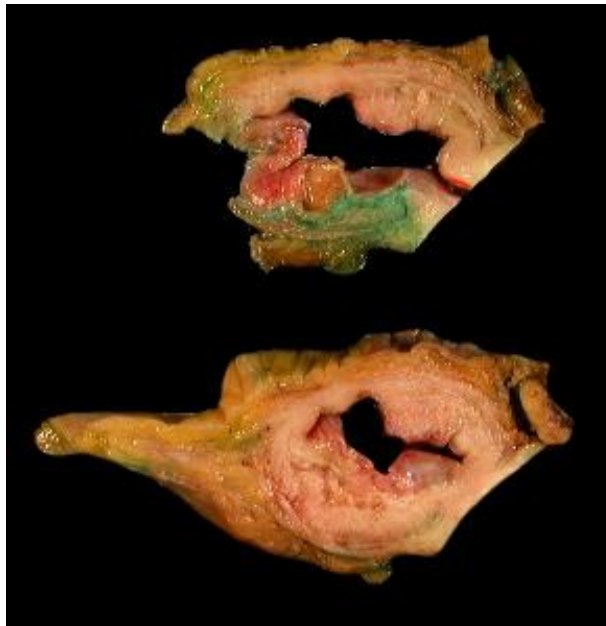
11. Remove the prostate from the bladder.



12. Sample the bladder:

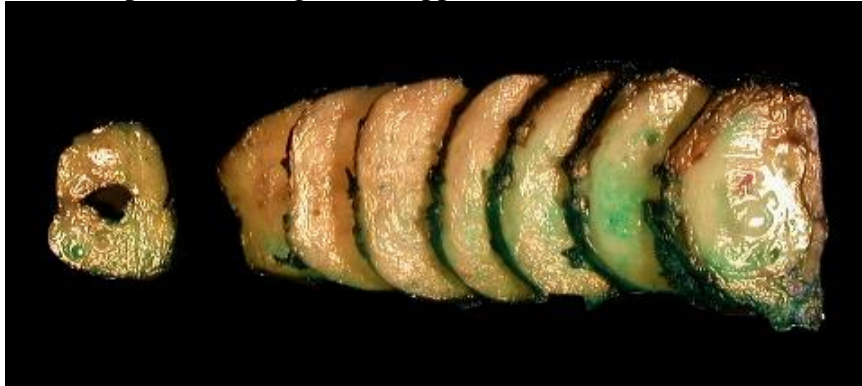- a. Dome
- b. Left lateral wall
- c. Right lateral wall
- d. Anterior wall
- e. Posterior wall
- f. Trigone
- g. Left ureteric orifice
- h. Right ureteric orifice
- i. Tumour or Ulcer bed

13. If only ulcer is present then take all of this area. Big blocks of the bladder are useful but these should be no thicker than 4mm.



Author: Jon Oxley
Authorised by:
Date: 23/08/2004

14. Take **ALL** the prostate in big blocks approx 3-4mm thick.



15. The seminal vesicles only need to be sampled if involved by tumour or if prostate cancer is known/found.

16. Place the urethral margin distal surface down and order 3 levels (often no urothelium is seen).

17. Report using standard proformas.

Author: Jon Oxley
Authorised by:
Date: 23/08/2004